

*Case Report***Effectiveness of Dysphagia Rehabilitation in a Post-cardiac Surgery Patient Who Leads a Social Life**

Masahiro Ikeno, Speech Therapist, Doctor (Sensory Science),¹ Hiromichi Metani, Medical Doctor, Doctor (Medical Science),² Shinya Fukunaga, Speech Therapist, Doctor (Medical Science),¹ Akio Tsubahara, Medical Doctor, Doctor (Medical Science)³

¹Department of Sensory Science, Faculty of Health Science and Technology, Kawasaki University of Medical Welfare, Kurashiki, Okayama, Japan

²Department of Rehabilitation Medicine, Kawasaki Medical School, Okayama, Okayama, Japan

³Management Division of Kawasaki University of Medical Welfare, Kurashiki, Okayama, Japan

ABSTRACT

Ikeno M, Metani H, Fukunaga S, Tsubahara A. Effectiveness of Dysphagia Rehabilitation in a Post-cardiac Surgery Patient Who Leads a Social Life. *Jpn J Compr Rehabil Sci* 2016; 7: 39–44.

Many patients are reported to experience dysphagia following thoracotomy, and there is a high rate of persistence of dysphagia as a result of prolonged endotracheal intubation. The importance of appropriate postoperative evaluation and rehabilitation has also been reported. A patient who had dysphagia following thoracotomy but recovered the ability for oral intake by undergoing long-term dysphagia rehabilitation in the active community-living phase (home care phase) is reported. The patient was a 90-year-old man diagnosed with severe dysphagia on the basis of recurrent laryngeal nerve paralysis following thoracotomy. The patient received a gastrostomy and was placed on home care. The patient visited our hospital 6 months after surgery, during which time his function had worsened due to his lack of oral intake ability. A videofluoroscopic swallowing study was performed after the patient presented at our hospital on the basis of information received from the patient's care manager. This was followed by tongue movement exercises and the chin push-pull maneuver. Directly thereafter, swallowing exercises were initiated with simultaneous introduction of compensatory techniques (postural adjustments, conscious swallowing). Eight

months after surgery, the patient was capable of full oral intake. The mechanisms by which dysphagia improved in the present case were likely the spontaneous healing of postoperative recurrent laryngeal nerve paralysis and the efficacy of exercises for recovering from swallowing function disuse that occurred during the period when he was incapable of oral intake. The rehabilitation of the present patient suggested that specialized and continuous evaluation and rehabilitative intervention are needed even at the stage of transition to the active community-living phase.

Key words: community-living phase rehabilitation, medical cooperation, dysphagia

Introduction

The incidence of dysphagia following thoracotomy is estimated to be 4.7%–24.5% [1]. Barker et al. reported dysphagia in 51% of the patients they examined who underwent prolonged endotracheal intubation after cardiectomy [2]. Meanwhile, dysphagia following extubation of cardiovascular disease patients can be improved to allow oral intake within a certain period of time by performing in-depth evaluation and active rehabilitation after surgery. However, the recent aging of Japanese society has resulted in more patients with reduced swallowing reserve capacity and greater recognition of the need for postoperative dysphagia rehabilitation for elderly individuals with the potential for dysphagia, thereby increasing demand for such rehabilitation [3].

We are also faced with the need to shorten hospital stays in acute care where the Diagnosis Procedure Combination system has been introduced. Furthermore, the population of Japan is aging at a globally unprecedented rate, and the elderly population of those aged ≥75 years will reach approximately 35

Correspondence: Masahiro Ikeno, Speech Therapist, Doctor (Sensory Science)

Kawasaki University of Medical Welfare, 288, Matsushima, Kurashiki-shi, Okayama 701-0193, Japan.

E-mail: ikeno@mw.kawasaki-m.ac.jp

Accepted: May 10, 2016

There are no conflicts of interest associated with this case report.

million by 2025. In light of this, elderly individuals with residual severe dysphagia will be at risk of not receiving treatment and sufficient dysphagia rehabilitation.

The patient reported in the present paper presented with severe dysphagia following thoracotomy at an acute hospital and received a gastrostomy. The patient lived with his family at home for 6 months without receiving any information on active community-living phase dysphagia rehabilitation from the acute hospital.

After 6 months, the patient finally visited our hospital upon receiving information from his care manager. The patient became capable of full oral intake following eight outpatient visits for rehabilitation including evaluation and exercise guidance for rehabilitation at home.

Based on the results of this case, it was found that dysphagia rehabilitation cannot be completed in the acute and recovery phases alone; active dysphagia rehabilitation is also important in the post-discharge phase when the patient is actively living in the community. Thus, this case is reported together with a discussion.

Case

The patient was a 90-year-old man who expressed a desire to eat orally. The patient had no history of dysphagia or other condition prior to his illness and had no comorbidities. Around the end of 201X, the patient developed dyspnea. He was diagnosed with mitral insufficiency at his local hospital (hospital A) and underwent mitral and tricuspid valvuloplasty and left atrial appendage closure at specialist hospital B in the middle of the following month. The day after surgery, the patient developed difficulty drinking and was diagnosed with left recurrent laryngeal nerve paralysis by laryngeal endoscopy and placed on nasogastric tube feeding. After being transferred to general hospital C, the patient was diagnosed with severe dysphagia after aspiration was seen under all conditions and with all food forms on videofluorography (VF). The patient also received a gastrostomy after it was explained that his chances of recovering his ability for oral intake were low despite continued rehabilitation. He was then discharged home. Following discharge, the patient received home-based rehabilitation (physiotherapy) by a visiting physiotherapist following a care assessment by his care manager, but received no functional training for dysphagia. Thereafter, the care manager provided information on dysphagia rehabilitation, and on postoperative day 214, the patient consulted our department with the wish to undergo dysphagia evaluation and outpatient rehabilitation.

Initial Findings

The findings at the patient's initial visit to our hospital (first outpatient visit on postoperative day 214) were as follows.

1. Medical interview

The patient lived together with his son and his son's wife and was independent in activities of daily living. He had been spending all day at home while receiving home-based rehabilitation for the purpose of stabilizing his outdoor walking and increasing his stamina. All nutritional intake was through the gastrostomy, and the patient had suffered no reduced nutritional status or weight loss. The patient did not ingest food orally in daily living and was merely capable of gargling cold water during oral care. The patient did not choke on water during gargling and had no fever or other symptoms suggestive of aspiration pneumonia. The patient had a nursing care requirement level of 1.

2. Cognitive function

No clear cognitive dysfunction was seen.

3. Speech function

In free conversation, the patient did not exhibit any decreased speech intelligibility suggestive of dysarthria. Furthermore, no breathy hoarseness typical of recurrent laryngeal nerve paralysis was noted at the initial visit to our hospital.

4. Swallowing function

In screening tests, the patient was not able to swallow in the repetitive saliva swallowing test (RSST) and achieved grade 3 in the modified water swallow test (MWST). While choking was noted in the MWST, breathing was good, with no decrease in blood oxygen saturation (SpO₂). No clear problems with tongue or lip movement occurred in the oral preparatory phase or oral phase during observation of swallowing.

5. VF examination

In the first VF examination, the patient ingested 0.5–1 ml of mayonnaise-like thickened food while in a 30° reclining position. Self-expectoration was possible despite aspiration occurring before and after swallowing. Unlike upward displacement of the hyoid bone, no forward displacement of the hyoid bone was seen during the swallowing reflex (Table 1). Based on the results of various examinations, the patient was deemed to have Grade 2 swallowing ability according to Fujishima's Grade [4], indicating that only basic dysphagia training was suitable. The problems identified were weakness of the laryngeal elevator muscles and impaired bolus transfer from the back of the tongue to the pharynx.

Course after Commencement of Training

Speech-language therapy was scheduled once every 1–2 weeks on an outpatient basis, resulting in the patient undergoing seven training sessions in 3 months (2nd to 8th sessions: postoperative days 223–312).

Table 1. VF results.

Day of illness	186	248			328		
Intake angle	30°	90°	90°	90°	90°	90°	90°
Form	Extremely thick	Slightly thick	Water without thickener	Banana	Slightly thick	Water without thickener	Banana
Chewing/crushing	—	—	—	3	—	—	3
Intraoral retention	2	3	3	3	3	3	3
Bolus formation	2	2	2	2	2	2	3
Intraoral residue	2	2	2	2	2	2	3
Transfer to the pharynx	2	2	2	2	2	2	3
Delayed swallowing reflex	2	3	3	3	3	3	3
Oral reflux	3	3	3	3	3	3	3
Nasopharyngeal reflux	3	3	3	3	3	3	3
Reflexive choking	2	2	2	2	2	2	2
Expectoration of aspirated material	2	2	2	1	2	2	2
Residue in epiglottal vallecula	3	3	3	3	3	3	3
Residue in pyriform sinus	1	1	1	1	1	1	1
Passage through esophageal inlet	1	2	2	1	2	2	1
Laryngeal penetration	1	2	2	2	2	2	2
Aspiration	1	2	2	2	2	2	2
Residue in esophagus	3	3	3	3	3	3	3
Esophageal reflux	3	3	3	3	3	3	3

Based on the results of initial tests, the patient was given guidance during the speech-language therapy sessions on independent tasks to perform at home concurrently with the chin push-pull maneuver [5] and tongue movement exercises designed to improve bolus transfer to the back of the tongue. During the third visit (postoperative day 228), swallowing reflex initiation on instruction to swallow saliva had improved. The MWST was performed again, but no decrease in SpO₂ or wet hoarseness was noted after swallowing. Because the patient had a habit of tilting his neck backward when swallowing, he was instructed to consciously swallow with the chin down. In independent training, the patient was capable of appropriate indirect training and postural adjustment.

In the second VF examination (postoperative day 248; Table 1), the patient ingested 3 ml of potage-like water with thickener, 3 ml of unthickened fluid, and a banana while sitting at 90°. While the unthickened fluid penetrated the larynx, and the banana was aspirated after swallowing, the patient was able to self-expectorate by coughing. Overall, movement during the oral bolus transfer phase had improved.

In light of the improvement in swallowing function seen on the VF examination results, jelly intake exercises were initiated on an outpatient basis alone from the 5th visit (postoperative day 248). Initially, the

patient complained of pharyngeal residue; he had to swallow multiple times, but was gradually able to swallow without leaving residue in a single swallowing reflex. The presence or absence of residue was confirmed by neck auscultation. During ingestion of jelly, there was no choking, and breathing was stable. Because no fever or decreased SpO₂ suggestive of pneumonia was noted at this time, oral intake of a concentrated liquid diet with added thickener was initiated from the 6th visit (postoperative day 270). By the time of the 7th visit (postoperative day 284), the patient had been able to gradually increase his intake of a concentrated liquid diet at home. The patient also had an extremely strong appetite and was able to comprehend which foods were easy or difficult to swallow. By the 8th visit (postoperative day 312), the patient was progressing well, with a score of 5 on the RSST and a grade of 5 on the MWST.

In the third VF examination (postoperative day 328; Table 1), the patient ingested 3 mL of soup-like thickened food and a banana while sitting at 90°. No aspiration or laryngeal penetration was noted with any of the food forms. While some residue was seen in the epiglottic vallecula with the banana, the patient was able to remove this residue by swallowing again.

On the basis of the results of the re-evaluation, the patient was deemed to have grade 9 swallowing ability

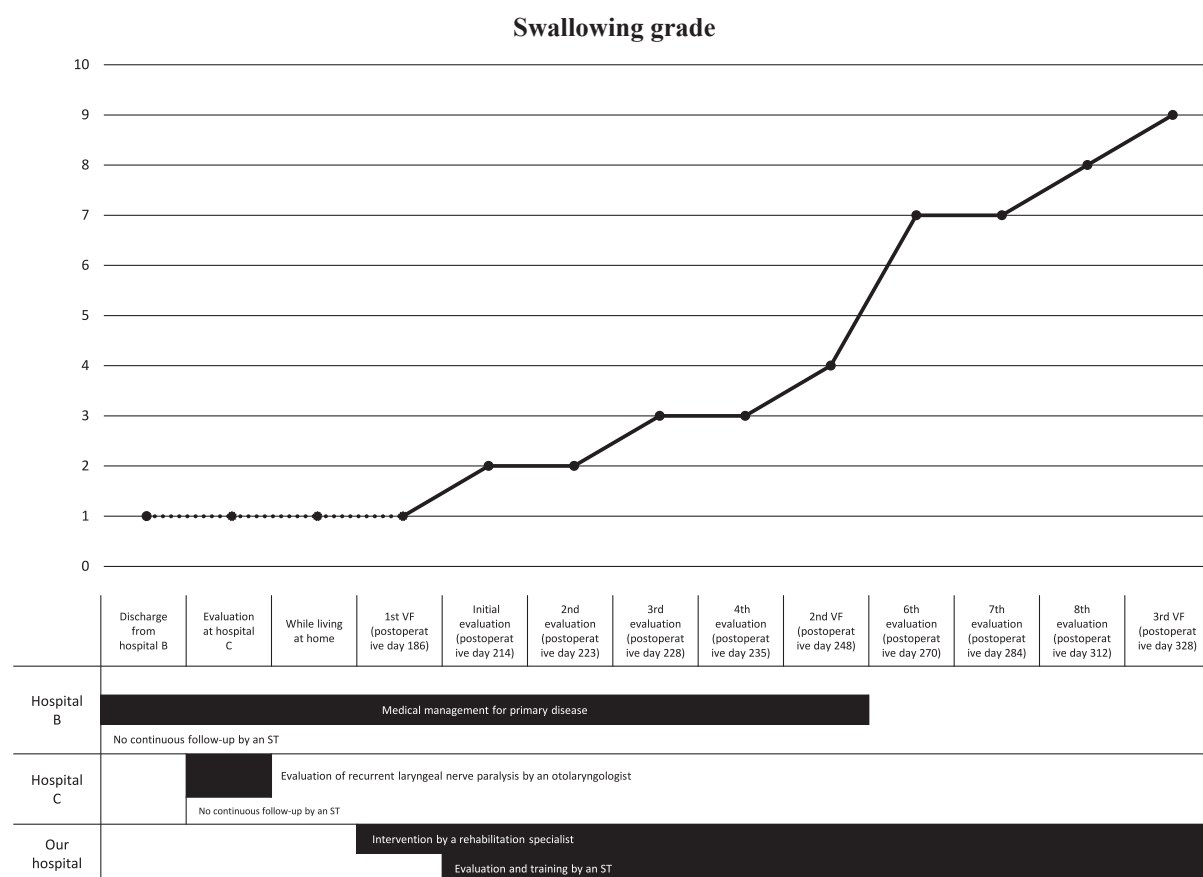


Figure 1. Progress until visiting our hospital and changes in swallowing grade.

(capable of oral intake of a regular diet and requiring clinical observation and guidance). The patient's outpatient training was completed once he was deemed capable of eating three meals under family supervision (Figure 1).

Discussion

Several reports have been published regarding aspiration caused by recurrent laryngeal nerve injury following cardiovascular surgery [6–9]. The prognosis for recurrent laryngeal nerve paralysis is often improved with early intervention. Moreover, to prevent suffocation and aspiration pneumonia, early intervention involving careful evaluation followed by active rehabilitation is vital [10].

In the elderly, organic and functional changes are considered to decrease systemic function and reduce swallowing function through disuse [11]. Disuse of swallowing function is considered a factor behind the decrease in swallowing frequency [12]. This decrease in swallowing frequency is reportedly caused by factors such as the introduction of tube feeding, reduced opportunities to stimulate the oral cavity through conversation and other means, and reduced salivary secretion due to oral medication [11].

The present patient received no medical management

for his heart disease, either during his hospitalization or after his discharge to home, and was not approached regarding his dysphagia. Even after receiving his gastrostomy, the patient was given little information in the community and underwent no active dysphagia rehabilitation, because no intervention by a speech-language therapist was provided.

However, the patient was able to improve his dysphagia by undergoing dysphagia rehabilitation on an outpatient basis from 6 months after discharge. While a definitive diagnosis was not possible in this case because no videoendoscopic swallowing study was done, the likelihood of spontaneous healing of the recurrent laryngeal nerve paralysis during the period of home care was considered strong, because the patient exhibited no dysphonia such as breathy hoarseness at his initial visit. On the other hand, the present patient was a 90-year-old man who had experienced reduced swallowing frequency due to tube feeding and fewer opportunities for intraoral stimulation with just home care from the time of creation of his gastrostomy to his first visit to our hospital, which suggested the presence of several factors causing disuse. Considering the fact that the present patient, who exhibited aspiration during his initial VF examination, was capable of oral intake following dysphagia rehabilitation and experienced

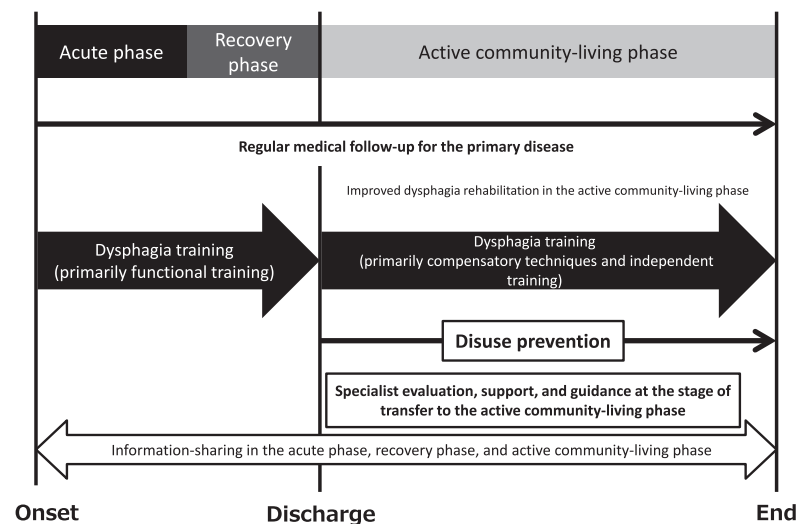


Figure 2. Ideal comprehensive rehabilitation system.

spontaneous healing of recurrent laryngeal nerve paralysis, it is conceivable that recovery of oral intake was achieved by performing muscle strengthening training and compensatory techniques, which improved the functional decline resulting from disuse.

The fact that the patient was unable to undergo continuous dysphagia rehabilitation from the acute phase to the recovery and active community-living phases may have had an impact. This suggests that, in the present case, specialist intervention based on community care conferences was needed prior to healing of the recurrent laryngeal nerve paralysis. If swallowing evaluation had been performed sooner, even in the active community-living phase, the patient might have achieved oral intake sooner without developing swallowing problems due to disuse.

The recent trend toward shorter hospital stays in the acute and recovery phases might increase the number of patients whose treatment will need to be entrusted to welfare facilities in the active community-living phase. If acute and convalescent hospitals provide sufficient information to long-term care insurance facilities regarding the swallowing functional evaluations and treatment progress of patients, treatment in the active community-living phase could be carried out more smoothly. It is also important to further examine methods of sharing information. On the other hand, even if acute hospitals offer sufficient rehabilitation and provide information to the community, disuse may still increase in regions with welfare facilities that cannot continue treatment due to a lack of specialists. Going forward, it will be crucial to improve long-term care insurance facilities responsible for active community-living phase treatment and to enhance case conferences in order to promote a comprehensive community care system (Figure 2).

The community in which the present patient lives is in the process of transitioning from “hospital-contained”

care to “community-contained” care, and it is not providing ideal support under these circumstances. This suggests the need for comprehensive support for every aspect of a patient’s disability, regardless of the primary disease, in future healthcare cooperation.

Conclusions

This report described a patient diagnosed with severe dysphagia on the basis of recurrent laryngeal nerve paralysis following surgery for heart disease, who recovered the ability for oral intake by undergoing dysphagia rehabilitation initiated in the active community-living phase. Dysphagia often coexists in patients who have experienced a stroke, and while stroke patients undergo consistent rehabilitation from the acute phase to the recovery phase, findings suggest that patients with other diseases are left to recover without intervention for dysphagia. In addition to clarifying which patients do not receive dysphagia rehabilitation in the active community-living phase, it will also be important to establish a support system for dysphagia for all diseases within the comprehensive community care system.

References

1. Leder SB, Suiter DM, Duffey D, Judson BL. Vocal fold immobility and aspiration status: a direct replication study. *Dysphagia* 2012; 27: 265–70.
2. Barker J, Martino R, Reichardt B, Hickey EJ, Ralph-Edwards A. Incidence and impact of dysphagia in patients receiving prolonged endotracheal intubation after cardiac surgery. *Can J Surg* 2009; 52: 119–24.
3. Skoretz SA, Rebeyka DM. Dysphagia following cardiovascular surgery: a clinical overview. *Can J Cardiovasc Nurs* 2009; 19: 10–6.
4. Fujishima I. Rehabilitation for swallowing disorders associated with stroke. 1st ed. Tokyo: Ishiyaku Co., Ltd.; 1993. p.72.

5. Iwata Y, Terashima K, Nagashima K, Hattori T, Horibe S, Okada T, et al. The chin push-pull maneuver as a means of training for swallowing function in elderly people: Effects of self-training. *Jibi to Rinsho* 2010; 56 Suppl 2: 195–201.
6. Shafei H, El-Kholy A, Azmy S, Ebrahim M, al-Ebrahim K. Vocal cord dysfunction after cardiac surgery: an overlooked complication. *Eur J Cardiothorac Surg* 1997; 11: 564–6.
7. Kawahito S, Kitahata H, Kimura H, Tanaka K, Oshita S. Recurrent laryngeal nerve palsy after cardiovascular surgery: relationship to the placement of a transesophageal echocardiographic probe. *J Cardiothorac Vasc Anesth* 1999; 13: 528–31.
8. Wilson JA, Pryde A, White A, Maher L, Maran AG. Swallowing performance in patients with vocal fold motion impairment. *Dysphagia* 1995; 10: 149–54.
9. Shin T, Maeyama T, Morikawa I, Nakaaki K. Aspiration caused by recurrent laryngeal nerve paralysis. *Jibi to Rinsho* 1985; 31 Suppl 2: 416–20.
10. Leder SB, Suiter DM, Duffey D, Judson BL. Vocal fold immobility and aspiration status: a direct replication study. *Dysphagia* 2012; 27: 265–70.
11. Fujitani J. Aging process and disuse syndrome in swallowing ability. *Gen Rehabil* 2006; 34: 637–41.
12. Tanaka N, Nohara K, Kodani Y, Tsuji S, Matsumura M, Sakai T. Swallowing frequency in elderly people during daily life. *Jpn J Dysphagia Rehabil* 2013; 17: 145–52.